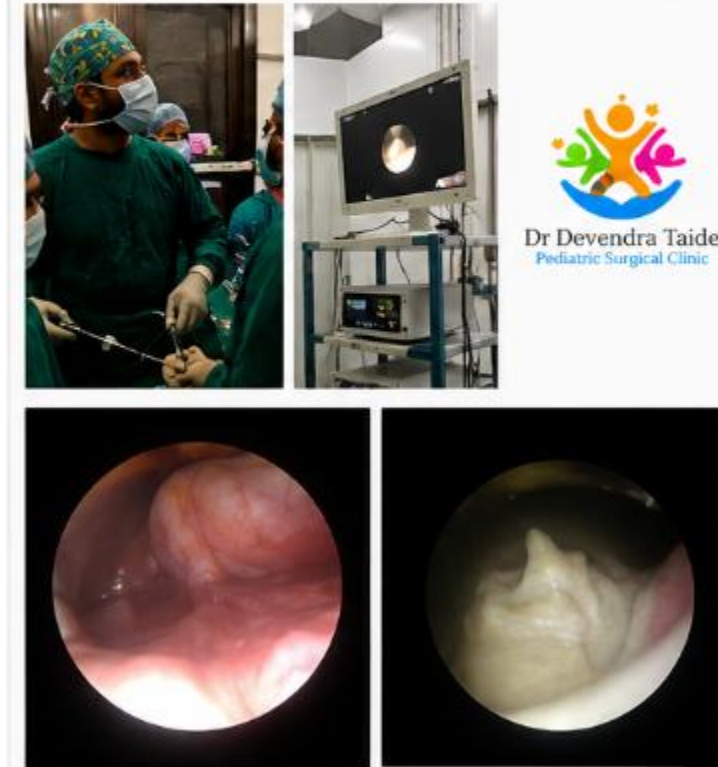


## NEONATAL ENDO-UROLOGY – LARGE URETEROCELE



  
Dr Devendra Taide  
Pediatric Surgical Clinic

### Neonatal Endo-Urology – Large Ureterocele

#### Overview

A newborn was diagnosed with a **large ureterocele**, a cystic dilatation of the distal ureter within the bladder, leading to urinary obstruction and potential risk to renal function if left untreated.

#### Procedure

A **minimally invasive endoscopic incision (ureterocele decompression)** was performed using pediatric cystoscopy. The ureterocele was incised to allow free drainage of urine, relieving obstruction while preserving renal function.

#### Outcome

- Immediate decompression of the ureterocele
- Improved urinary drainage and bladder function

- No perioperative complications

### **Key Highlights**

- Completely **endoscopic (scarless) procedure**
- Avoided open surgery in a newborn
- Early intervention prevented long-term renal damage
- Demonstrates expertise in **pediatric urology and neonatal endo-urology in Thane**